

Recurrence of Radial Bowing After Soft Tissue Distraction and Subsequent Radialization for Radial Longitudinal Deficiency

Caroline Dana, MD, Jean-Charles Aurégan, MD, Arielle Salon, MD, Stéphane Guéro, MD, Christophe Glorion, MD, Stéphanie Pannier, MD, PhD

Purpose Centralization and radialization are the most widely reported surgical treatments for Bayne and Klug Type III and IV radial longitudinal deficiency. Prior soft tissue distraction has been introduced to improve reducibility of the deformity without skeletal resection. Satisfying long-term effects have been reported with centralization but are still unclear with radialization.

Methods This is a retrospective study of 8 consecutive children with Bayne and Klug Type III or IV radial longitudinal deficiency treated with preliminary soft tissue distraction followed by radialization between 2003 and 2008. All children underwent the same surgical protocol. End points of the study were clinical appearance, the hand-forearm angle, and mean angular correction at last follow-up.

Results The mean preoperative hand-forearm angle was 61° (26° – 91°). The average duration of distraction was 1.9 month (1–3 mo). The initial postoperative angle averaged 12° (-14° – 40°). There were 3 postoperative complications: 2 cases of pin loosening and 1 case of fracture of the base of the small finger metacarpal. Mean follow-up duration was 2.6 years (1–4 y). At last follow-up, 7 of the 8 patients had visible recurrence of the deformity, the hand-forearm angle had deteriorated to 44° (20° – 69°), and the mean angular correction was 18° (-43° – 59°).

Conclusions Preoperative distraction allows a gradual realignment of the hand on the forearm without skeletal resection, but the recurrence rate after radialization is high. Tendon transfers and soft tissue tensioning were unable to maintain hand-forearm alignment following soft tissue distraction. (*J Hand Surg* 2012;37A:2082–2087. Copyright © 2012 by the American Society for Surgery of the Hand. All rights reserved.)

Type of study/level of evidence Therapeutic IV.

Key words Radial longitudinal deficiency, soft tissue distraction, radialization.

RADIAL LONGITUDINAL DEFICIENCY is characterized by a shortened forearm with radial deviation of the hand and thumb hypoplasia. Incidence is between 1 in 30,000 and 1 in 100,000 births with a slight female predominance (60%).^{1,2} About 38% to

58% of cases are bilateral with a right-sided predomination.^{3–5} The malformation occurs between the fourth and the eighth week of the embryonic period with a defective development of the radial aspect of forearm and hand. It results in bone abnormalities, but the mus-

From the Necker-Enfants Malades Hospital, Department of Pediatric Orthopedics, University Paris Descartes, Paris, France.

Received for publication February 23, 2012; accepted in revised form July 17, 2012.

No benefits in any form have been received or will be received related directly or indirectly to the subject of this article.

The authors would like to thank Robert J. Strauch, MD, and Ryan M. Coyle, BA, from Columbia University (New York, NY) for their help improving the quality of this research and the writing of the manuscript.

Corresponding author: Jean-Charles Aurégan, MD, Necker-Enfants Malades Hospital, Department of Pediatric Orthopedics, University Paris Descartes, 149 rue de Sèvres, 75015 Paris, France; e-mail: aureganjc@yahoo.fr.

0363-5023/12/37A10-0019\$36.00/0
<http://dx.doi.org/10.1016/j.jhsa.2012.07.018>

cles, nerves, vessels, and joints are also affected to various degrees. Radial longitudinal deficiency can occur in isolation, after exposure to teratogenic drugs, or in many cases, as part of a syndrome. The most frequently reported are the Holt-Oram syndrome, VATER/VACTERL (vertebral anomalies, anal atresia, cardiac abnormalities, tracheoesophageal fistula, renal agenesis, and limb defects), the Fanconi syndrome, thrombocytopenia-absent radius syndrome, and trisomy 13 and 18.^{6–12} In 1987, Bayne and Klug¹³ introduced a 4-part classification.

The aim of the treatment of radial longitudinal deficiency is to improve the function and appearance of the upper limb. Current regimens start from birth with stretching and splinting in order to lengthen the soft tissues and obtain the reduction of the deformity. For Bayne and Klug Types III and IV, surgical treatment is often indicated and aims to realign the hand on the forearm. Since the first description of a surgical approach by Sayre in 1893, 2 surgical techniques have become popular: centralization and radialization.^{14–16} The aim of centralization is to place the carpus on the ulna in line with the long finger metacarpal and to maintain this position until adulthood. It allows durable realignment but can restrict wrist mobility and longitudinal ulna growth because carpal and distal ulnar resection is frequently required.¹⁵ The aim of radialization is to overcorrect the radial deviation deformity by aligning the distal ulna with the index metacarpal and transfer tendons from the radial to the ulnar side of the forearm in order to actively maintain this position.¹⁶ Until now, neither of the 2 techniques has proven superior.⁵

In 1989, Kessler described a technique to passively distract the soft tissues with an external fixator before centralization.¹⁷ It enabled better postoperative correction without the need for skeletal shortening. Prior soft tissue distraction has also been combined with radialization but the long-term effects on outcome remain unclear.¹⁸

In order to determine the maintenance of surgical correction obtained after soft tissue distraction followed by radialization, we report a series of 8 consecutive children with Bayne and Klug Types III and IV radial longitudinal deficiency with at least a 1-year follow-up treated by this technique.

MATERIALS AND METHODS

We reviewed retrospectively the cases of Bayne and Klug Type III or IV radial longitudinal deficiency treated with prior soft tissue distraction and radialization in our institution. Our purpose was to evaluate the

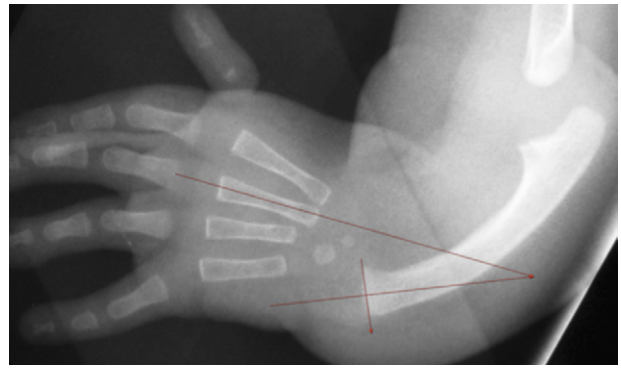


FIGURE 1: Hand-forearm angle according to Geck et al.⁵

rate of recurrence of the deformation at least 1 year later. The inclusion criterion was every child with Bayne and Klug Type III or IV radial longitudinal deficiency treated with a 2-stage procedure combining a prior soft tissue distraction and a radialization and a minimal postoperative follow-up longer than 1 year. Exclusion criteria were a systemic disease that might affect the functional outcomes, poor compliance with treatment, and irregular monitoring. The retrospective review of medical charts and patients was conducted according to the recommendations of the ethical committee board, and all patients' parents gave their written informed consent.

For preoperative clinical status, we reported the sex, the age at time of surgery, and every associated clinical abnormality. The radial longitudinal deficiency was characterized by Bayne and Klug's classification, and the hypoplasia of the thumb by the Blauth classification modified by Buck-Gramcko.¹⁹ For preoperative radiological criteria, we used those developed by Manske et al. in 1981²⁰ and popularized by Geck et al. in 1999.⁵ The measurements were made on an anteroposterior radiograph covering the hand and the complete forearm in order to estimate the hand-forearm angle or forearm-hand corner (Figure 1). Only radiographs that were taken in our institution according to the protocol of the radiology department were included for analysis. The hand-forearm angle was defined by the intersection between the line passing longitudinally through the shaft of the small finger metacarpal and the line perpendicular to the bisector of the ulnar epiphysis. By definition, the angle is positive in case of radial deviation and negative in case of ulnar deviation.

The surgical treatment was staged, a soft tissue distraction followed by a radialization. Three different senior surgeons (S.P., A.S., and S.G.) used the same surgical protocol. The first procedure was a gradual soft tissue distraction by a monoplane external fixator. In 7

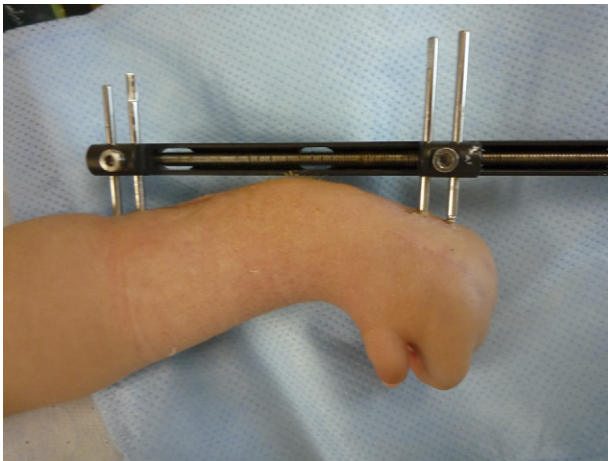


FIGURE 2: Example of a rail fixator applied along the dorsal side of the forearm with 2 pins in the ulnar diaphysis and 2 pins in the ring finger metacarpal.

cases, the external fixator was a rail fixator applied along the dorsal side of the forearm with 2 pins in the ulnar diaphysis and 2 pins in the ring finger metacarpal (Figure 2). For 1 patient, 1 surgeon (S.P.) used from habit an external fixator with a multidirectional hinge applied along the ulnar side of the forearm with 2 pins in the ulnar diaphysis and 2 pins in the small finger metacarpal. A progressive distraction of 0.5 mm to 1 mm a day was applied to the deformity in order to gradually stretch the radial soft tissues. Palmar subluxation of the hand/carpus on the distal ulna was investigated at each examination to avoid a false sense of correction. Unusual pain, skin tightness, and/or finger stiffness were screened as indications of excessive traction and led to a slowing of the rate of distraction. As soon as passive correction was achieved, the second procedure was performed. This procedure was a radialization and consisted of external fixator removal, followed by radialization and temporary hand-forearm pinning in overcorrection according to Buck-Gramcko.¹⁶ An S-shaped incision was then made from the dorsal aspect of the hand to the proximal third of the forearm. The dorsal and radial muscles were assessed for transfer to the ulnar side of wrist. A temporary pin transfixing the index finger metacarpal and the ulna secured the wrist in slight overcorrection. The extensor retinaculum and tendons were isolated and preserved. The median nerve, usually located dorsally and tensed in the concavity of the deformity, was identified and protected. Fibrotic material on the radial side of the hand was excised. The joint capsule was incised longitudinally. The radial collateral ligament was preserved if well developed. If a cartilaginous remnant of the distal radius was found, it was removed to improve

reducibility. At this stage, overcorrection of the deformity was obtained. The temporary pin was removed and a 1.8-mm Kirschner wire was inserted from proximal to distal through the radial carpus and index finger metacarpal and then withdrawn distally. The hand was placed in slight ulnar deviation, and the pin was advanced proximally into the ulna without breaching the skin. The previously isolated radial muscles were then transferred to the ulnar side and sutured laterally to the extensor carpi ulnaris. The ulnar collateral ligament and capsule remnants were sutured to the periosteum forming a neoligament. Before closing, the excess skin on the ulnar side was partially excised. Postoperative care consisted of immobilization with a brachio-palmar orthosis for 3 to 6 weeks. No hand therapy was prescribed. Pin removal was carried out at 6 weeks for 7 patients and at 7 weeks for 1 patient to coincide with the date of the thumb surgery. After pin removal, nonspecific active-passive hand therapy was encouraged. Children were examined at 6 weeks, 3 months, and then every 6 months after radialization. Each time, a physical examination assessing the maintenance of the correction and function of the tendon transfers was performed. Orthogonal radiographs of the forearm were performed at 3 months, 6 months, and every following year if needed.

The primary end point of the study was a clinical recurrence of the radial deformity at last follow-up. Secondary end points were hand-forearm angle at last follow-up and the loss of correction between the forearm-hand angle immediately following radialization and at last follow-up. Complications and reoperations were recorded.

Continuous data were expressed by average, standard deviation, minimum, and maximum. We used a paired *t*-test to compare the preoperative and final postoperative hand-forearm angles. *P* less than .05 was considered statistically significant.

RESULTS

Between 2003 and 2008, 8 consecutive patients with a Bayne and Klug type III or IV radial longitudinal deficiency were treated with a soft tissue distraction and secondary radialization in our institution (Table 1). All the patients met the inclusion criteria and none was excluded. There were 6 boys and 2 girls. The mean age at the beginning of distraction was 2.0 years with a range from 6 months to 5 years. Associated abnormalities involved VACTERL syndrome in 2 cases, Townes Brocks syndrome in 1 case, and an undetermined syndrome in 3 cases. In 2 cases, the radial longitudinal deficiency was an isolated anomaly. The radial longi-

TABLE 1. Patients' Characteristics

Patient	Age (y)	Radial Longitudinal Deficiency Classification	Thumb Classification	Associated Malformations	Distraction Duration (mo)	Predistraction Angle (°)	Postoperative Angle (°)	Correction (degrees)	Complications	Follow-up (y)	Final Angle (°)	Deformity Recurrence	Final Correction (°)
1	1	Type IV	Grade V	Vertebral malformations/ cleft palate	2	43	8	35	None	4	40	Yes	3
2	3	Type IV	Grade IV	Vertebral malformations/ intraventricular communication	2	31	-14	45	None	4	40	Yes	-9
3	1.7	Type IV	NR	VACTERL	1	84	8	76	Poor performance of pin	3	51	Yes	33
4	1.8	Type IV	Grade V	None	2	91	20	71	None	3	50	Yes	41
5	5	Type IV	Grade II	VACTERL	1.5	51	24	27	Small finger metacarpal fracture	3	40	Yes	11
6	0.5	Type III	Grade IV	None	2	84	8	76	None	2	38	Yes	46
7	1.3	Type IV	Grade IV	Townes Brocks syndrome	2	26	0	26	Poor performance of pin	1	69	Yes	-43
8	1.3	Type IV	Grade IV	Myelomeningocele/mental retardation	3	79	40	39	None	1	20	No	59

VACTERL, vertebral anomalies, anal atresia, cardiac abnormalities, tracheoesophageal fistula, renal agenesis, and limb defects; NR, not reported.

tudinal deficiency was a Bayne and Klug Type III in 1 case and Type IV in 7 cases. The thumb hypoplasia was classified as Grade II in 1 case, Grade IV in 4 cases, and Grade V in 2 cases. In 1 case, it was not reported. The mean hand-forearm angle before distraction was 61° (SD, 26; range, 26°–91°). Eight procedures with external fixator distraction before radialization were performed. Seven of them were performed as initial surgery, and 1 was performed after failure of a previous procedure (radialization alone). The average duration of distraction was 1.9 months (SD, 0.6; range, 1–3 mo). After radialization, the initial postoperative angle averaged 12° (SD, 16; range, -14°–40°). Comparison of the pre- and postoperative hand-forearm angle showed a mean angular correction of 51° (SD, 23; range, 26°–76°).

Mean follow-up duration was 2.6 years (SD, 1.2; range, 1–4 y). No patient was lost to follow-up. At last follow-up, 7 of the 8 patients had a recurrence of the radial deformity. The forearm-hand angle at last follow-up was 44° (SD, 14; range, 20°–69°). Comparison of the hand-forearm angle before surgery and at last follow-up showed a mean angular correction of 18° (SD, 34; range, -43°–59°). Comparison of the preoperative and the final postoperative hand-forearm angles by the paired *t*-test led to a *P* of .182. We were unable to conclude that a statistically significant difference existed between the preoperative hand-forearm angle and the hand-forearm angle at last follow-up. No intraoperative complication occurred. There were 3 postoperative complications: 2 cases of loosening of the proximal pins, necessitating changing, and 1 occurrence of fracture of the base of the small finger metacarpal. This complication occurred in the patient with the distal pins placed in the small finger metacarpal.

DISCUSSION

Treatment of radial longitudinal deficiency remains challenging. The natural history of radial longitudinal deficiency is generally a worsening of the deformity with stiffness in radial deviation, palmar subluxation of the carpus, and aggravation of the ulnar bowing.⁸ When surgical management of a radial longitudinal deficiency is indicated, variable techniques are available. The techniques most reported in the literature are centralization and radialization. These techniques have provided good anatomical and functional results in both the short term and the long term.^{8,16} In 1989, Kessler described a soft tissue distraction by an external fixator before centralization.¹⁷ It aimed to enable the centralization procedure without skeletal resection and with decreased tension of the soft tissues. This staged procedure has

proved effective when combined with centralization.^{17,21–26} Nanchahal and Tonkin¹⁸ used the same procedure before radialization, showing that postoperative angles were comparable with traditional centralization.

Before the introduction of preliminary soft tissue distraction by an external fixator, we preferred to use centralization because the carpal resection facilitated reduction of the deformity. With the introduction of preliminary soft tissue distraction, we switched from centralization to radialization when it was possible. The final decision was made after our intraoperative muscle exploration. If the radial muscles were present and their quality seemed acceptable, radialization with tendon transfer was preferred; if the radial muscles were poor, then centralization with prolonged pinning was performed without carpal resection.²⁷ Poor-quality muscles were expected, especially in Type IV radial longitudinal deficiency and Grade 4 or 5 thumb hypoplasia in which the radial tendons are often represented only by an abnormal and hypoplastic extensor digitorum communis. Therefore, we used the presence of the extensor carpi radialis and extensor indicis proprius along with normal tendon insertions to assess the quality of our transfers. All the patients of our series had an extensor carpi radialis and an extensor indicis proprius, both with normal insertions. Although their thickness had to be suitable for suturing, no systematic measurement of their length or diameter was made.

Buck-Gramcko¹⁶ reported satisfactory long-term results in his original series of radialization. Although his results were not reported with objective measures, we were surprised by the average final angle in our series (44°) because we expected to combine the immediate advantages of the soft tissue distraction with the long-term results of radialization. Various articles report the results of prior soft tissue distraction by external fixator for the surgical treatment of Bayne and Klug Types III and IV radial longitudinal deficiency.^{18,22–26,28} The average preoperative hand-forearm angles reported ranged from 53° to 96°. The various series presented variable distraction and surgical protocols, with mean postdistraction angles from –5° to 15°, corresponding to a mean correction of 38° to 89°. Those values are comparable with our results of a postdistraction angle of 12° and a mean angular correction of 51°. But only 3 series presented their results at last follow-up.^{24–26} Those results were 18°, 5°, and 10°, respectively, of mean hand-forearm angle with only 5 clinical recurrences out of 43 patients for 5, 2.5, and 1.5 years of follow-up, respectively. However, each of the 3 series used centralization as their corrective procedure with

the additional creation of a carpal notch in order to increase stability in Kanojia et al.'s²⁵ and Saini et al.'s²⁶ series. Moreover, Saini et al.²⁶ used a prolonged pinning, which improved long-term stability and considerably lowered recurrences.

Geck et al.⁵ listed the possible causes of radial deviation recurrence: inadequate intraoperative correction, failure to release the radial side soft tissues, premature removal of the ulnar pin, and inability to balance the radial forces. Buck-Gramcko¹⁶ attributed the poor results in his series to advanced operative age or to inadequate quality of the transferred muscle. Our distraction technique did not differ regarding the type, speed, and duration of distraction from those previously reported, and our average postdistraction angle of 12° indicated that the distraction was probably not the main cause.^{17,18} Moreover, aware of the importance of a good radial side release during radialization, we paid careful attention to this aspect of the surgery. However, we can retrospectively suspect that radial transfers failed to protect against recurrence of the deformity. As we performed the fixation of the radial tendons to the extensor carpi ulnaris with nonabsorbable sutures, we suggest that an alternative method of fixation, such as tendon to bone, could be considered to potentially strengthen those transfers.

We observed recurrences in the first year after radialization with a progressive worsening indicating that these transfers were a possible cause of failure. However, many authors using preoperative distraction do not use tendon transfers, so not using tendon transfers is not likely the only explanation for recurrence.^{17,18,22} In our series, 7 of the 8 radial aplasias developed recurrence of the deformation after removal of the pinning, sometimes rapidly (patient 7). Delorme²⁹ recommended a prolonged pinning in order to reduce the risk of recurrence. With prolonged fixation until adulthood, a durable hand-forearm alignment would be ensured while respecting bone growth and avoiding bowing and carpal dislocation. However, this would necessitate changing the pins regularly during the forearm's growth and sacrificing wrist motion during childhood. Searching for the other explanations of these recurrences, our analysis regarding the age at the first surgery and angulation greater than 35° was not conclusive given the small size of the series.

Finally, 1 case (patient 8) illustrates the particular difficulty of treating patients with radial longitudinal deficiency. This patient was born with a Type IV deformity along with myelomeningocele and slight mental retardation. The preoperative hand-forearm angle was 79° and was associated with a palmar subluxation

of the carpus. The distraction was for 3 months without obtaining satisfactory alignment. The postradialization angle was 40°. The correction was, however, maintained with no clinical evidence of recurrence at 1 year. There are 2 possible explanations for this absence of recurrence. First, the short follow-up and second, an ulnocarpal stiffness secondary to the prolonged ineffective dorsal distraction on the palmar subluxation. However, we used a monoplane external fixator for the preliminary soft tissue distraction as described by Smith and Greene.²² Goldfarb et al.²¹ discouraged the use of monoplane external fixators after observing several cases with poor results because the distraction was located only on the ulnar side of the forearm. They preferred a circumferential external fixator to increase stability and correct the deformity more accurately.

REFERENCES

- Birch Jensen A. Congenital deformities of the upper extremities. Copenhagen: Ejnar Munksgaard, 1949.
- Urban MA, Osterman AL. Management of radial dysplasia. *Hand Clin* 1990;6:589–605.
- Kato K. Congenital absence of radius. *J Bone Joint Surg* 1924;6:589–626.
- Lourie GM, Lins RE. Radial longitudinal deficiency. *Hand Clin* 1998;14:85–99.
- Geck MJ, Dorey F, Lawrence JF, Johnson MK. Congenital radius deficiency: radiographic outcome and survivorship analysis. *J Hand Surg* 1999;24A:1132–1144.
- Verloes A, Frikiche A, Gremillet C, Paquay T, Decortis T, Rigo J, et al. Proximal phocomelia and radial ray aplasia in fetal valproic syndrome. *Eur J Pediatr* 1990;149:266–267.
- Holt M, Oram S. Familial heart disease with skeletal malformations. *Br Heart J* 1960;22:236–242.
- Lamb DW. Radial club hand. A continuing study of sixty-eight patients with one hundred and seventeen club hands. *J Bone Joint Surg* 1977;59A:1–13.
- Fanconi G. Familiäre infantile perniziösaartige Anämie (perniziöses Blutbild und Konstitution). *Jahrbuch für Kinderheilkunde und physische Erziehung*. Vienna: 1927;117:257–280.
- Hall JG, Levin J, Kuhn JP, Ottenheimer EJ, van Berkum KA, McKusick VA. Thrombocytopenia with absent radius (TAR). *Medicine (Baltimore)* 1969;48:411–439.
- Moraine C, Laugier J, Grenier B, Desbuquois G. Trisomy 13. *Ann Pediatr (Paris)* 1972;19:121–137.
- Sepulveda W, Treadwell MC, Fisk NM. Prenatal detection of pre-axial upper limb reduction in trisomy 18. *Obstet Gynecol* 1995;85:847–850.
- Bayne LG, Klug MS. Long-term review of the surgical treatment of radial deficiencies. *J Hand Surg* 1987;12A:169–179.
- Sayre PA. A contribution to the study of club hand. *Trans Am Orthop Assoc* 1893;6:208–216.
- Watson HK, Beebe RD, Cruz NI. A centralization procedure for radial club hand. *J Hand Surg* 1984;9A:541–547.
- Buck-Gramcko D. Radialization as a new treatment for radial club hand. *J Hand Surg* 1985;10A:964–968.
- Kessler I. Centralisation of the radial club hand by gradual distraction. *J Hand Surg* 1989;14B:37–42.
- Nanchahal J, Tonkin MA. Pre-operative distraction lengthening for radial longitudinal deficiency. *J Hand Surg* 1996;21B:103–107.
- Buck-Gramcko D. Congenital malformations of the hand and forearm. *Chir Main* 2002;21:70–101.
- Manske PR, McCarroll HR Jr, Swanson K. Centralization of the radial club hand: an ulnar surgical approach. *J Hand Surg* 1981;6:423–433.
- Goldfarb CA, Klepps SJ, Dailey LA, Manske PR. Functional outcome after centralization for radius dysplasia. *J Hand Surg* 2002;27A:118–124.
- Smith AA, Greene TL. Preliminary soft tissue distraction in congenital forearm deficiency. *J Hand Surg* 1995;20A:420–424.
- Sabharwal S, Finuoli AL, Ghobadi F. Pre-centralization soft tissue distraction for Bayne type IV congenital radial deficiency in children. *J Pediatr Orthop* 2005;25:377–381.
- Taghinia AH, Al-Sheikh AA, Upton J. Preoperative soft-tissue distraction for radial longitudinal deficiency: an analysis of indications and outcomes. *Plast Reconstr Surg* 2007;120:1305–1312.
- Kanojia RK, Sharma N, Kapoor SK. Preliminary soft tissue distraction using external fixator in radial club hand. *J Hand Surg* 2008;33E:622–627.
- Saini N, Patni P, Gupta S, Chaudhary L, Sharma V. Management of radial clubhand with gradual distraction followed by centralization. *Indian J Orthop* 2009;43:292–300.
- Guéro S. Les mains botes radiales. In: *Cahiers d'Enseignement de la Société Française de Chirurgie de la Main*. Paris: Elsevier 1999:97–100.
- Goldfarb CA, Murtha YM, Gordon JE, Manske PR. Soft-tissue distraction with a ring external fixator before centralization for radial longitudinal deficiency. *J Hand Surg* 2006;31A:952–959.
- Delorme T. Treatment of congenital absence of the radius by transepiphyseal fixation. *J Bone Joint Surg* 1969;51A:117–129.