

# Post-traumatic distal interphalangeal finger joint reconstruction using a free hemi-joint transfer from the fifth toe middle phalanx

Arielle Salon<sup>a</sup>, Pierre Journeau<sup>b</sup> and Jean Luc Drape<sup>c</sup>

**We present three cases of finger distal interphalangeal joint reconstruction in children using a new donor site, the middle phalanx of the fifth toe, transferred as a non-vascularized graft. The patients were followed a minimum of 36 months with serial radiographs, magnetic resonance imaging and photographs. Alignment was improved and persisting growth was demonstrated in all cases. Post-operative magnetic resonance imaging of the grafted phalanx and control toe showed comparable signals. The absence of a proximal epiphysis of these toe phalanges may have an important role in their survival after free transplantation, and may promote continued growth. *J Pediatr Orthop B* 14:116–119 © 2005 Lippincott Williams & Wilkins.**

## Introduction

Free toe phalanx transfers have become an accepted procedure for the treatment of congenital hand deformities, but are less often used in secondary post-traumatic indications. We have had to deal with several cases of distal interphalangeal (DIP) deviation and epiphysiodesis after crush injuries in very young children. Cosmetic impairment due to a short and crooked digital extremity was the immediate motivation for reconstruction, but parents were most anxious about growth arrest predictable on radiographs. Parents were informed that a simple method to correct deviation could be an osteotomy or a DIP arthrodesis.

However, together with the families, we chose to realign the DIP joint and attempt to restore some growth in one procedure, using a free hemi-joint transfer of an intercalary toe phalanx. The smallest phalanx potentially available for transfer was naturally the middle phalanx of the fifth toe. The fifth toe middle phalanx behaves like a chondroepiphysis, which is different from other phalanges transferred so far. It also has the right dimensions for a free half-joint transfer, replacing the base of a terminal phalanx when deviated and epiphysiodesis applied after crush injury. Parents were aware that the overall size of the reconstructed digit may not be normal, and that the proposed reconstruction was an experimental but logical attempt to recover some joint motion and growth, with minimal expense on the donor site. The more ambitious alternative of free vascularized articular transfer was not considered, because it was a much larger surgical intervention.

1060-152X © 2005 Lippincott Williams & Wilkins

*Journal of Pediatric Orthopaedics B* 2005, 14:116–119

**Keywords:** finger distal interphalangeal joint, epiphysiodesis, free toe phalanx transfer, growth

<sup>a</sup>Orthopaedic Paediatric Surgery Department, Necker Enfants Malades Hospital, Paris, <sup>b</sup>Orthopaedic Paediatric Surgery Department, Brabois Hospital, CHU de Nancy, Allée du Morvan, 54511 Vandoeuvre, France, <sup>c</sup>Radiology Department, Cochin Hospital, Paris, France.

Correspondence and requests for reprints to Pierre Journeau, MD, Assistant Professor, Orthopaedic Paediatric Surgery Department, Hôpital d'Enfant, CHU de Nancy, Allée du Morvan, 54511 Vandoeuvre, France.  
Tel: +33 3 83 15 47 07; fax: +33 3 83 15 46 93;  
e-mail: p.journeau@chu-nancy.fr

## Patients and methods

DIP deviation and epiphysiodesis of the terminal phalanx after severe crush injury was found in three young children (age at trauma, 2–4 years). All three had open, displaced growth plate injuries. They had been managed initially by open reduction and pinning. Deformity was already apparent 1 year after trauma (Fig. 1), but surgery was delayed due to diverging therapeutic advice. Ages and clinical features are detailed in Table 1. All three children were scheduled for a free fifth toe second phalanx transfer.

The DIP joint was exposed through a transversal, dorsal approach. Flexion deformity and lateral deviation of the distal phalanx were corrected by subperiosteal anterior or lateral release, through a trans-articular dorsal exposure. No anterior arthrotomy was done, to avoid scarring or devascularization. Fibrous tissue at the base of the terminal phalanx was resected, creating a gap corresponding to the entire proximal epiphysis. Collateral ligaments and the volar plate were preserved.

The second phalanx of the little toe was harvested with the periosteum, the proximal joint capsule and collateral ligaments. The distal articular part of the toe second phalanx was trimmed to obtain intimate bone to bone contact with distal remnants of the finger terminal phalanx. The toe phalanx was skewered on a 0.8 mm or 1.0 mm Kirshner wire and pinned for 4–6 weeks with the reconstructed DIP joint in 0° extension. The collateral ligaments were not repaired, but were left to attach by adhesions. The dorsal capsule and extensor tendon were

approximated with thin absorbable sutures. At the donor site, the flexor and extensor tendons of the toe were not sutured together, to promote a shorter, but active fifth toe.

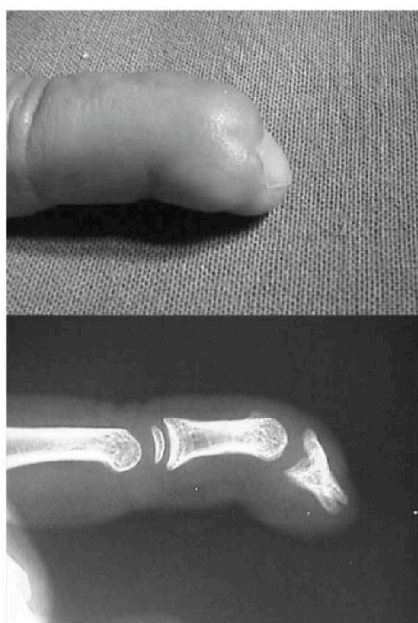During follow-up of these children, score of satisfaction assessed by the child or his parents (bad, fair, good, very good) and detailed clinical features of angular correction of DIP deviation, length, cosmetic aspect and joint motion of both finger and donor toe were recorded. Antero-posterior and lateral radiographs and photographs of the operated finger, contralateral finger and fifth toe were taken to monitor axial growth and appearance. Magnetic resonance imaging (MRI) of the grafted finger and of the control non-operated opposite fifth toe

investigated joint surfaces, vitality of the phalanges and growth structures 6 months postoperatively, using a high spatial resolution surface coil with T1 and T2-weighted sequences.

## Results

Follow-up was at 43 (case 1), 42 (case 2) and 36 (case 3) months. All fingers were cosmetically improved, and satisfaction was high (two very good, one good). The two deviated and stiff DIP joints had an angular correction of 50° and 40°, resulting in normal alignment, and recovered 20° and 10° of active motion (Table 1 and Fig. 2). The preoperatively unstable DIP (case 2) recovered the best mobility (0–60° active motion). Radiograph showed that all grafted phalanges were united to the terminal phalanx at 6 weeks.

Fig. 1



Four-year-old girl 2 years after trauma (case 1). Sixty degrees flexion deformity, shortening and hammer-like aspect due to terminal phalanx epiphysodesis.

No distal bony resorption occurred in any of the cases. Radiographically, the grafted phalanges grew in the same proportion at follow-up as did the control toe. MRI confirmed that control fifth toe middle phalanges did not have a classic proximal epiphysis and behaved as flat bones, with peripheral growth. In comparison, all proximal and distal toe phalanges, and the middle phalanx of the second and third toes behaved as long bones, with a proximal epiphysis whatever the age.

The grafted phalanx at 6 months had a normal and intermediate signal intensity on unenhanced T1-weighted images on MRI and the articular surface of the grafted phalanx appeared regular (Fig. 3).

## Discussion

The indication for reconstructing and realigning the DIP joint seems justified by the conservation of a good fingertip. The need to correct DIP range of motion and to restore some growth to the terminal phalanx brought us to a free toe phalanx transfer.

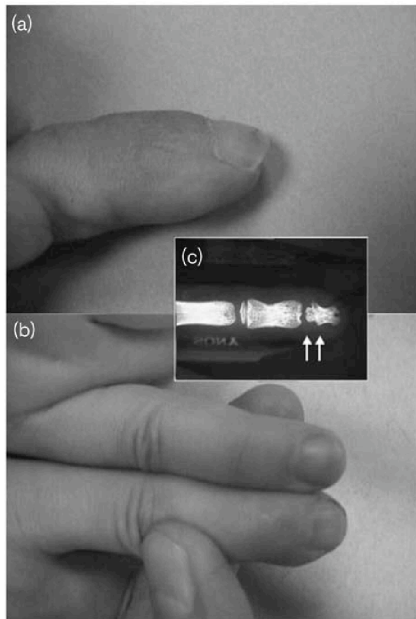
Buck-Gramcko [1] has widely popularized this technique in congenital cases. He emphasized that the aim of a free phalanx transfer is not only stabilization and lengthening of aplastic digits but also the transfer of a hemi-joint to

Table 1 Patient ages and clinical features

Case	1	2	3
Age at trauma (years)	2	4	2
Age at surgery (years)	4	5	10
Preoperative appearance	Hammer-like tip, 60° DIP flexion deformity, short extremity	Unstable, very short extremity	Flexion deformity 40°, lateral deviation 40°, short extremity
Radiograph	Proximal epiphysodesis of third phalanx	Proximal epiphysodesis and resorption of third phalanx	Epiphysodesis of third phalanx
Follow-up (months)	43	42	36
Active DIP flexion–extension (°)	10–30	0–60	0–10
Postoperative deviation	None	None	None
Postoperative radiograph	Graft fused, no evidence of growth arrest, no resorption of terminal phalanx	Graft fused, no evidence of growth arrest, no resorption of terminal phalanx	Graft fused, bone maturity achieved, no resorption of terminal phalanx

DIP, distal interphalangeal.

Fig. 2

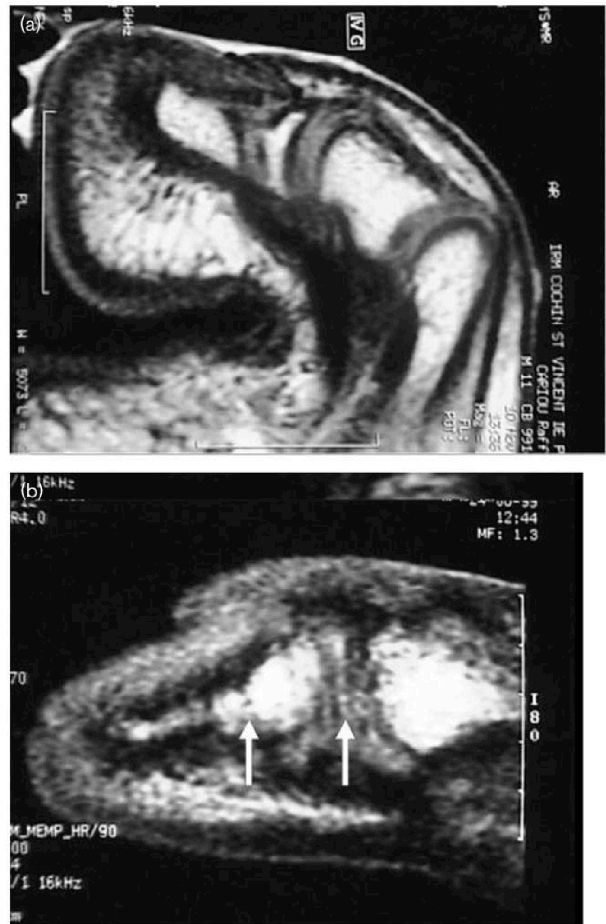

Appearance at 30 months. (a) Ten degrees residual flexion of distal interphalangeal joint. (b) Comparative length of both index fingers. (c) Radiograph shows incorporation of toe phalanx graft (arrows), and a wide, normal looking articular space.

obtain mobility. He was the first author to report on joint motion at follow-up in a large series. Free phalanges have also been used, less frequently, in post-traumatic cases, with encouraging results on length [2–4]. These results encouraged our choice for a growing free half-joint transfer, as opposed to a vascularized microsurgical transfer, which in any case the parents of our patients did not approve.

There are several advantages to the use of fifth toe middle phalanges to reconstruct terminal phalanx injuries affecting the DIP joint and terminal phalanx growth plate in children. The shape and size are adequate for the purpose. Length is not as much of an issue in traumatic as opposed to congenital defects, when final size of the digit is the challenge. In symbrachydactyly, proximal phalanges are commonly preferred for transfers, because restoration of length is an important consideration. Some authors preferred to use the proximal phalanx from the third or fourth toe to avoid a possible deformity and instability. Cavallo [5] described this possible complication, but he never used a phalanx transfer from the fifth toe in his series. We never observed these problems using the fifth toe, maybe because we did not perform a suture with flexor and extensor tendons together. Therefore, the fifth toe is progressively and moderately shortened, without instability or deformity (Fig. 4). For the DIP joint one

Fig. 3

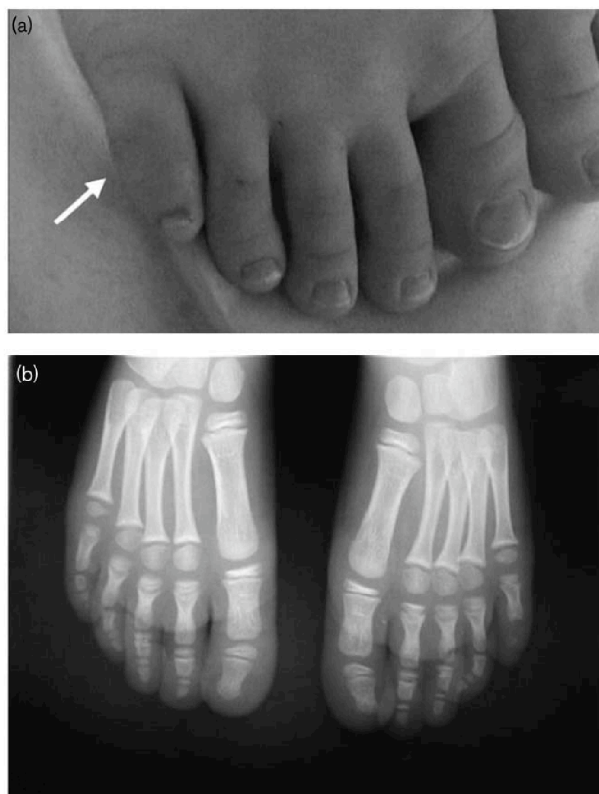


(a) Magnetic resonance imaging (MRI) of the control fifth toe (opposite side of donor toe for middle phalanx). Middle phalanx, between both arrows, of the normal fifth toe has no visible proximal epiphysis, although the child is only 4 years old. Note the growth plate of the distal phalanx of this fifth toe. (b) Index finger distal interphalangeal (DIP) joint on the same MRI sequence. The grafted middle phalanx is between the two arrows and has the same signal 6 months postoperatively as the control middle phalanx of the contralateral fifth toe on MRI above. The graft is fused distally to the terminal phalanx. Note similar joint intervals of control toe for proximal interphalangeal and reconstructed finger distal interphalangeal joints.

only needs a small spacer and a hemi-articular transfer with some growth reserve. The middle phalanx of the fifth toe is the smallest in the human body, and naturally appeared as the ideal donor. It had the periosteum required for growth, and the cosmetic and functional expense on a little toe is negligible.

A second advantage is the growth pattern, compared with all other phalanges. We learned from our experience with congenital symbrachydactyly that fifth toe middle phalanges had no visible proximal epiphysis. The cartilaginous proximal epiphyses often present in the proximal

Fig. 4



(a) Clinical aspect of the fifth toe in case 1 at latest review. There is no cosmetic deformity, minimal shortening is present, and the toe is mobile and stable. (b) The radiographic control at the latest follow-up of both feet (donor site is the left foot).

phalanx of the fifth toe, but without development of secondary ossification centre. Fifth toe middle phalanges are not, like most other phalanges, long bones with a proximal growth plate but instead behave like flat bones, with subarticular chondroepiphysis. We validated this fact prospectively on a continuous series of 450 radiographs of children of all ages, from 1998 to the present. We confirmed this observation also by high-resolution MRI on children aged 2–12 years.

The question of growth of free phalanx transfers is a very important one. The role of periosteum in phalangeal growth has been established [1,6], but the role of the physis and its patency is most debated. It demonstrated that a physeal transfer must survive 7–10 days of

avascularity before successful incorporation can occur and longitudinal growth can resume. During that period the graft is nourished by tissue fluid alone. Buck-Gramcko showed that by three postoperative years all proximal epiphysis were fused on transferred toe first phalanges. In our cases, the occurrence of growth arrest could not be evaluated by physeal patency on radiographs because of the special behaviour of the proximal physis, as a chondro-epiphysis or flat bone with peripheral growth. This could make them possibly more resistant to ischaemia after avascular transfer.

The only possible radiographic evaluation was to compare the size of the transferred and control toe middle phalanges. All three transferred toes grew symmetrically on scaled films, when compared with their control. The phalanges with longest follow-up showed no evidence of growth arrest on serial radiograph measures. MRI at 6 months showed no change in the epiphyseal bone or cartilage.

In conclusion, functional and cosmetic expense on the donor toe is negligible. They seem to us a very promising donor, particularly for half-joint reconstruction in children with DIP joint deformity after injuries involving the terminal phalanx growth plate, when a pre-shaped growing spacer is more important than immediate length.

### Acknowledgements

We are specially grateful to Dr Peter Amadio (Hand Surgery Department, Mayo Clinic, Rochester, Minnesota, USA) for reviewing the manuscript, and his kind help and advice.

We thank Dr Laurence Mainard (Paediatric Radiology Department, Brabois Hospital, CHU de Nancy, France) for his help with illustrations.

### References

- 1 Buck-Gramcko D, Pereira JAR. Proximal toe phalanx transplantation for bony stabilization and lengthening of partially aplastic digits. *Ann Chir Main Memb Super* 1990; **9**:107–118.
- 2 Snowdy HA, Omer GE, Sherman FC. Longitudinal growth of a free toe phalanx transplant to a finger. *J Hand Surg* 1980; **5**:71–73.
- 3 Vercauteren ME, Van Vynckt C. A free total toe phalanx transplant to a finger: a case report. *J Hand Surg* 1983; **8**:336–339.
- 4 Whitesides ES. Normal growth in a transplanted epiphysis. Case report with thirteen year follow-up. *J Bone Joint Surg Am* 1977; **59A**:546–548.
- 5 Cavallo AV, Smith PJ, Morley S, Morsi AW. Non-vascularized free toe phalanx transfers in congenital hand deformities: the Great Ormond Street experience. *J Hand Surg Br* 2003; **28**:520–527.
- 6 Goldberg NII, Watson KII. Composite toe (phalanx and epiphysis) transfers in the reconstruction of the aphalangic hand. *J Hand Surg Am* 1982; **7A**:454–459.